

CLINICAL FOCUS: RHEUMATOLOGY, PAIN MANAGEMENT AND CONCUSSION GUIDELINES
CASE REPORT

The role of the cervical spine in post-concussion syndrome

Cameron M. Marshall¹, Howard Vernon¹, John J. Leddy² and Bradley A. Baldwin³

¹Department of Graduate Studies, Canadian Memorial Chiropractic College, 6100 Leslie Street, Toronto, Ontario, Canada, ²Department of Physiology and Family Medicine, State University of New York at Buffalo, University Sports Medicine, 160 Farber Hall – SUNY, Buffalo, NY, USA, and ³Private Practice – Sports Medicine and Rehab Centres, 199 Mill Street, Angus, Ontario, Canada

Abstract

While much is known regarding the pathophysiology surrounding concussion injuries in the acute phase, there is little evidence to support many of the theorized etiologies to post-concussion syndrome (PCS); the chronic phase of concussion occurring in ~10–15% of concussed patients. This paper reviews the existing literature surrounding the numerous proposed theories of PCS and introduces another potential, and very treatable, cause of this chronic condition; cervical spine dysfunction due to concomitant whiplash-type injury. We also discuss a short case-series of five patients with diagnosed PCS having very favorable outcomes following various treatment and rehabilitative techniques aimed at restoring cervical spine function.

Keywords:

Brain concussion, post-concussion syndrome, whiplash injuries, pathophysiology, musculoskeletal manipulations

History

Received 10 March 2015

Accepted 17 June 2015

Introduction

Concussion injuries, or mild traumatic brain injury (mTBI), have an estimated prevalence of 3.8 million per year in the United States [1] and are considered one of the least understood injuries facing the sports medicine and neuroscience communities today [2]. In the majority of cases, concussion symptoms resolve within 7–10 days; however, ~10–15% of these patients develop persistent symptomatology lasting weeks, months or even years after injury [3–5]. Depending on the classification system used, post-concussion syndrome (PCS) is defined as the persistence of three or more symptoms for 4 weeks (International Classification of Diseases, Tenth Revision), or 3 months (Diagnostic and Statistical Manual of Mental Disorders), following a minor head injury [6–9].

The pathophysiology of mTBI during the acute phase of injury is becoming increasingly well-known suggesting ion imbalance, metabolic disruptions, blood flow abnormalities and autonomic nervous system (ANS) dysfunction as the main culprits [6,10–14]. When attempting to search for potential mechanisms surrounding PCS; however, findings have been inconsistent and there remains no clear physiologic explanation for this disorder [9,15]. In fact, most studies examining the physiologic dysfunctions found during the acute phase of concussion have demonstrated a return to baseline or control levels within 2–4 weeks following injury [6,12,13,16,17]. This has led to great debate within the medical community as to whether PCS is mainly a physiological or psychological manifestation following concussion injuries.

One proposed mechanism for persisting symptomatology that has not been examined in great detail is concomitant low-grade sprain–strain injury of the cervical spine occurring concurrently with significant head trauma. Based on the obvious anatomical association between head and neck, it is reasonable to expect that any significant blunt impact and/or acceleration/deceleration of the head will also result in some degree of inertial loading of the neck potentially resulting in strain injuries to the soft tissues and joints of the cervical spine. Studies in high school and college football players using the Head Impact Telemetry system have demonstrated that the range of linear impact accelerations causing concussion injury is between 60 and 160g (where ‘g’ represents gravity), with the highest predictive occurrence occurring at 96.1g [18]. Studies examining whiplash associated disorders (WAD) have demonstrated two very important features for our discussion: 1) biomechanical studies have demonstrated that as little as 4.5g of neck acceleration can cause mild strain injury to the tissues of the cervical spine [19] and 2) the signs and symptoms reported by these patients, with the exception of a few key differences (i.e. radicular symptoms), appear strikingly similar to those experienced in mTBI (Table 1) [20–28].

If an individual is to sustain an injury where the head is accelerated between 60 and 160g, it is highly likely that the tissues of the cervical spine have also reached their injury threshold of 4.5g. A 2006 study from the University of Guelph examined junior ‘A’ hockey players immediately following injuries that either appeared as whiplash mechanisms (i.e. a blow to the body with a whipping motion of the neck

Table 1. A comparison of signs and symptoms of concussion, from the post-concussion symptom score of the Sideline Concussion Assessment Tool version 3 (SCAT3) [3], and whiplash associated disorder (WAD), from the WAD Form C of the Quebec Task Force for Whiplash Associated Disorder [19].

Signs and symptoms of concussion	Signs and symptoms of WAD
Headache	Neck/shoulder pain
Pressure in head	Reduced/painful neck movements
Neck pain	Headache
Nausea/vomiting	Reduced/painful jaw movements
Dizziness	Numbness, tingling or pain in arm or hand
Blurred vision	Numbness, tingling or pain in leg or foot
Balance problems	Dizziness/unsteadiness
Sensitivity to light	Nausea/vomiting
Sensitivity to noise	Difficulty swallowing
Feeling slowed down	ringing in ears
Feeling like 'in a fog'	Memory problems
'Don't feel right'	Problems concentrating
Difficulty concentrating	Vision problems
Difficulty remembering	Lower back pain
Fatigue or low energy	
Confusion	
Drowsiness	
Trouble falling asleep	
More emotional	
Irritable	
Sadness	
Nervous or anxious	

and head), or injuries that appeared as concussion mechanisms (i.e. a direct blow to the head). It was discovered that 100% of the injured athletes had signs and symptoms of both WAD and concussion indicating that these injuries are happening concurrently [29].

Injury or dysfunction of the cervical spine has been shown to cause headaches [30,31], dizziness and loss of balance [32–34], nausea, visual and auditory disturbances [35], reduced cognitive function [19,26], and many other signs and symptoms considered synonymous with concussion. Interestingly, the limited studies involving functional imaging of the brain in these patients do not demonstrate any significant findings, which could indicate either psychological overlay or a true cervicogenic etiology to these symptoms [36,37].

This paper presents a review of the literature surrounding PCS, as well as cervical spine dysfunction to propose a theoretical hypothesis for mild cervical strain injury, suffered concurrently at the time of the concussion, acting as a major symptomatic culprit in many PCS patients. This paper also discusses the management of five PCS patients using both active rehabilitation and passive manual therapy of the cervical spine resulting in a significant reduction in symptoms as well as a significant improvement in function.

Pathophysiology of concussion and post-concussion syndrome

During concussive injury to the brain, previous literature demonstrates that neurons undergo stretch and shear forces that cause brief mechanical disruption of the cell structure, which leads to an indiscriminate exchange of ions, potassium (K^+) efflux, glutamate release and subsequent mitochondrial

calcium (Ca^{2+}) overload resulting in impaired oxidative metabolism and reduced ATP production. In an effort to restore proper ion balance within the cell, the ATP pump is activated to a greater capacity requiring large amounts of ATP. The imbalance between increased ATP requirements, decreased ATP production and reduced cerebral blood flow quickly leads to an energy crisis within the brain known as *spreading depression* (Figure 1) [10,14].

It is believed that the symptoms of concussion are due to reversible neuronal dysfunction and energy mismatch and not due to structural damage of the involved neurons, which is why conventional structural imaging techniques such as CT and MRI are typically unremarkable [3].

The vast majority of mTBI patients experience a resolution of symptoms within 7–10 days following injury [3]. There are a number of proposed reasons as to why roughly 10–15% of patients go on to experience longer lasting symptomatology, including both physiological and psychological etiology. Continued reductions of ATP, continued axonal dysfunction,

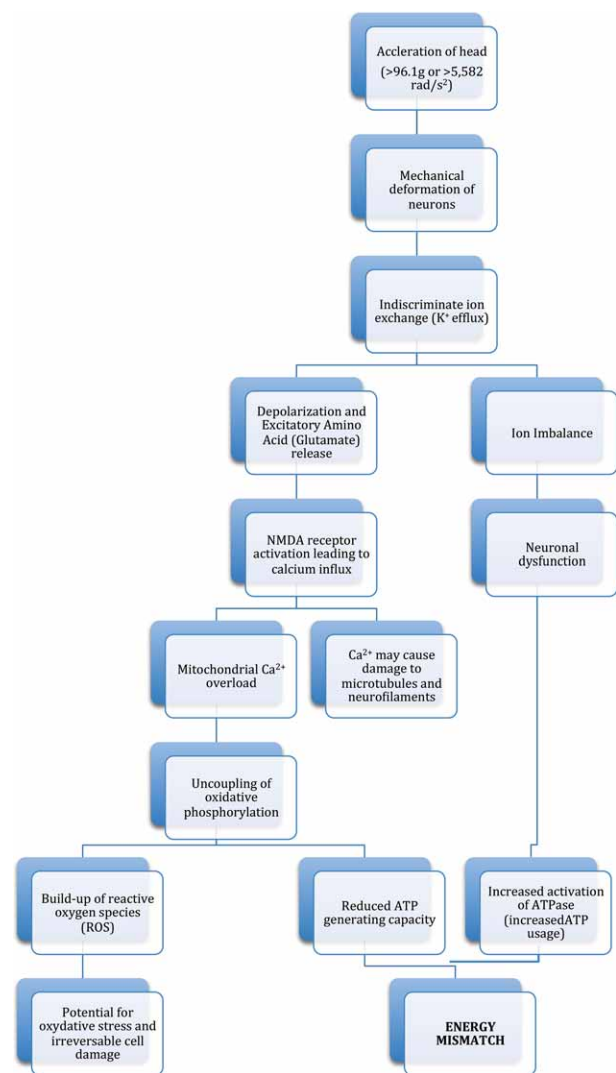


Figure 1. Neurometabolic Cascade of Concussion.

Reprinted with permission from the Journal of the Canadian Chiropractic Association [116].

Abbreviations: ATP = Adenosine Triphosphate; g = Gravity (9.8m/s²); NMDA = N-methyl-D-aspartate.

altered blood flow, continued ANS dysfunction have all been suggested as possible physiological alterations accompanying PCS; however, evidence surrounding each of these mechanisms is limited.

Theory 1: Continued metabolic dysfunction

Animal studies have demonstrated reductions in ATP as early as 1-min following impacts equivalent to concussion [38,39]. Unfortunately, ATP levels cannot be measured directly *in vivo* and therefore culling and processing must take place prior to direct ATP measurement. Proton magnetic resonance spectroscopy (MRS-H), however, is able to measure the concentration of metabolite levels, in particular N-acetyl aspartate (NAA), a high correlate of ATP levels ($R^2 = 0.84$) [17,39], within the brain of human subjects.

Human spectroscopy studies have demonstrated significant decreases in NAA: creatine and NAA: choline ratios in the acute phase of concussion; however, most return to non-injured control levels by 30 days post-injury (Figure 2) [13,40-43]. All subjects in these studies were asymptomatic within 8 days following injury; however, metabolite levels did not normalize until day 30. This indicates the likelihood of a weak correlation between symptoms and metabolic dysfunction.

One conflicting study came from Henry et al., in 2011 [44] where NAA: creatine ratios were still significantly reduced at 6 months post-injury in a group of 10 concussed football players as compared to an uninjured control group. Again, all concussed subjects were asymptomatic by the 6-month follow-up and had returned to full play. The authors posited that demands placed on the university athlete (i.e., course load coupled with intense practice and game schedules) may have been a hindrance to complete metabolic recovery [44].

The evidence of continued metabolic dysfunction in subjects diagnosed with PCS is limited [45] as most MRS-H studies have focused on the acute stages of injury or those with chronic impairment following more severe brain injuries. There have been two studies that have demonstrated metabolic reductions in symptomatic PCS patients; one in adult PCS patients [46] as well as pediatric PCS patients [47].

As previously mentioned, most studies demonstrate a return of concussion-related metabolites to control levels by 30 days following injury; however, suffering a second concussion during this metabolically depressed state has been shown to increase the time to NAA normalization in both animal and human subjects. In two human studies, symptomatic recovery took between 3 and 8 days following a single concussion. Following a second injury, suffered prior to NAA normalization, subjects reported significantly increased symptom durations, lasting between 24 and 59 days. A substantial delay in NAA normalization was also found in these doubly concussed athletes; ranging from 60 to 120 days post-injury [41,48]. These two studies not only highlight the importance of achieving full recovery before returning to sporting activity but also provide a potential physiologic basis for the increased propensity of PCS in patients with a previous concussion history.

The literature presented above demonstrates limited evidence for a metabolic justification for persistent concussion symptoms following a single concussive episode. Experiencing a second concussion prior to full metabolic recovery after the first has demonstrated persistent symptomatology and metabolic dysfunction in two separate case-series. Interestingly, in each of these cases (nine total), symptomatic recovery long preceded metabolic recovery, which leads one to question whether symptom recovery and metabolic recovery are closely related.

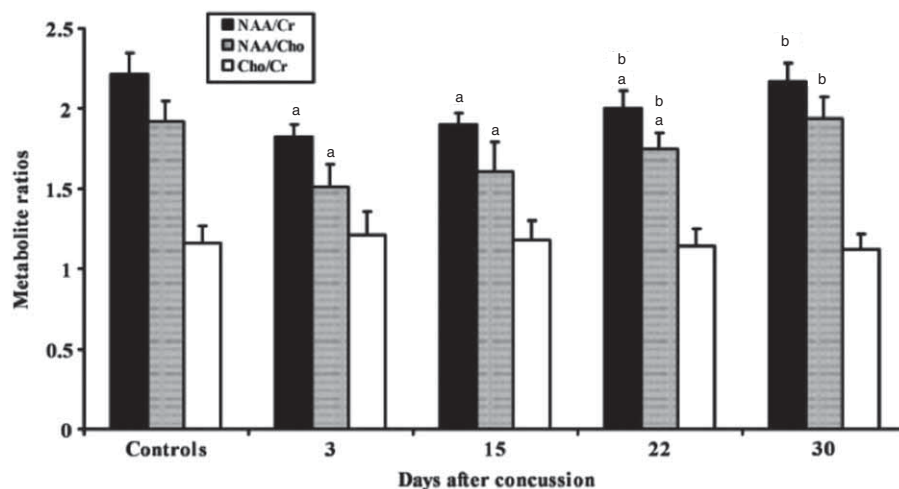


Figure 2. Cerebral metabolite ratios in controls versus sports concussion patients. Bar graph showing the metabolite ratios of N-acetyl aspartate/choline-containing (NAA/Cho) compounds, NAA/creatine-containing (NAA/Cr) compounds and choline-containing compounds/creatine-containing compounds (Cho/Cr) in controls and concussed patients. Each histogram is the mean value determined in 30 healthy controls and 40 concussed athletes in the study by Vagnozzi et al., 2010. At 3-days post-injury NAA/Cr is reduced by 17.6%, NAA/Cho is reduced by 21.4% with both gradually recovering to complete normalization at 30 days. The Cho/Cr ratio did not show any significant variation.

^a $p < 0.01$ with respect to controls.

^b $p < 0.01$ with respect to values determined at the previous time points.

Figure reprinted from [13] with permission from Oxford University Press.

Theory 2: Continued axonal dysfunction

Diffusion tensor imaging (DTI), an advanced imaging technique that assesses the integrity of white matter tracts by measuring the rate of water diffusion along, and perpendicular to, axonal fibers [49–51], has increased the understanding of concussion injuries substantially in recent years. The neuronal shearing that occurs with impact as well as the subsequent ion imbalance and Ca^{+} overload, can alter the cellular environment and brain function due to suggested myelin loss, microscopic lesions and axonal degeneration [49,52,53]. The three main measures of interest in DTI are *fractional anisotropy* (FA), *mean diffusivity* (MD) and *axial diffusivity*. Studies examining acutely concussed patients have found significant decreases in FA and significant increases in MD compared to controls [51,52], particularly in the posterior corpus callosum according to a recent meta-analysis [49]. On the contrary, other studies have shown increases in FA and decreases in radial diffusivity and MD [51,54] in almost equal numbers [55]. This inverse relationship between FA and MD is thought to represent damage to the microfilaments and microtubules of the axon [56]. However, like much of the research surrounding concussion injuries, as the scanning takes place further away from the initial injury most of the studies have shown variable results possibly attributed to inconsistent measurement methodology [49,53] or potential flaws within the measurement itself [55].

There have been a number of studies examining DTI in PCS patients in recent years [50,56–59], with mixed results when compared to uninjured controls. Comparing patients with ongoing symptomatology with uninjured, matched control groups is problematic for a number of reasons, especially when trying to elucidate the source of post-concussion symptoms. Lange et al., in one of the largest and most recent DTI PCS studies, examined 60 patients with recent mTBI (both asymptomatic and symptomatic patients) and compared them to 34 patients with orthopedic/soft tissue injuries (excluding cervical spine) between 6 and 8 months post-injury. Mild TBI subjects also completed a post-concussion symptom checklist and, based-upon the presence of three or more symptoms between 6 and 8 months post-injury, were classified as either being *post-concussional disorder* (PCD) present ($n = 21$), or PCD absent ($n = 39$). FA and MD values for various regions of the corpus callosum showed differences in all recent mTBI patients versus the orthopedic injury group; however, there were no significant differences found between those subjects classified as PCD present and those classified as PCD absent. The authors concluded that their data does not support an association between white matter integrity in the corpus callosum and post-concussion symptoms 6–8 months post-injury [60]. Recent research has also suggested that being involved in contact sports creates significant changes in various DTI parameters over the course of a season in athletes who have not suffered diagnosable injury [54,61,62].

In summary, despite early indications that microstructural brain injury can be evaluated using DTI, this imaging modality cannot currently predict PCS symptoms, clinical outcome and/or clinical recovery in individual subjects [51].

Furthermore, as the imaging takes place further from the time of the injury, results become less consistent and may not be associated with symptoms of PCS, but rather with a history of recent mTBI and/or involvement in contact sports.

Theory 3: Psychological factors

The diagnosis of PCS is complicated due to multiple symptoms that represent a myriad potential differential diagnoses with a large degree of psychological overlay. Among others, PCS has been shown to have similar presentations as depression, somatization and chronic pain [6]. It has also been suggested by numerous authors that preexisting psychological disturbances such as depression and anxiety increase the risk of developing PCS [3,63]. Although there is extensive research in this area, it is beyond the scope of this paper to provide a detailed review of this literature.

Theory 4: Altered cerebral blood flow

A common symptom observed in concussed athletes is the onset of post-concussion-like symptoms, particularly headache, when there is an increase in cardiovascular output during exercise [15]. One of the major hypotheses suggests that this is due to continued reductions in cerebral blood flow and oxygenation [6]. Reductions in cerebral blood flow have been found immediately following impact [10]. Other studies have found both increases as well as no change when examined within a day or two following injury [64,65]. Studies examining mTBI patients in the acute phase have also found ANS dysfunction such as altered cerebrovascular reactivity [11,66,67], cerebral autoregulation, cerebral oxygenation and heart rate variability [68] when compared to uninjured controls; however, these findings seem to normalize within 4–14 days post-injury [12,67,68]. Research surrounding these phenomena in PCS patients is, however, somewhat limited. To the authors' knowledge there have been no studies to date that have demonstrated similar autonomic dysfunctions in PCS subjects.

Single positron emission computed tomography (SPECT) is a resting state functional imaging technique used to examine cerebral blood flow using radioactive tracers, most commonly technetium-99 m-hexamethylpropyleneamine oxime ($^{99\text{m}}\text{Tc}$ -HMPAO) [45]. Studies using $^{99\text{m}}\text{Tc}$ -HMPAO SPECT in heterogeneous populations of chronic mTBI patients have demonstrated that between 40 and 60% demonstrate significant hypoperfusion in various regions of the brain. The most common areas cited for reduced blood flow in these studies are the frontal and parietal lobes [69–72]. At first glance, hypoperfusion of various cerebral levels may seem like a plausible explanation for post-concussion symptomatology and dysfunction; however, studies examining other entities such as chronic neck and upper thoracic pain [73], late-whiplash [23,74], acute and chronic low back pain [75], obsessive-compulsive disorder [76], depression [77], chronic fatigue syndrome, AIDS dementia complex [78] and many others have all demonstrated similar findings on SPECT. Furthermore, many chronic mTBI SPECT studies have not been able to

demonstrate consistent correlation with neuropsychological test results or post-concussion symptoms [45]. At this point, it seems that although cerebral hypoperfusion may be present in roughly half of PCS patients, this does not represent a specific etiology of chronic mTBI but rather a complex, non-specific finding that seems just as likely to appear in various chronic pain, anxiety and depression patients as it does in those diagnosed with chronic mTBI/PCS.

Case for a likely cervicogenic component to concussion injuries

Aside from the direct biomechanical associations and injury mechanics mentioned in the Introduction, the symptoms of headache and dizziness, so prevalent in concussion-type injuries, may actually be the result of cervicogenic mechanisms due to a concomitant whiplash injury suffered at the same time [22,29,79,80]. Two primary categories of mechanisms can be proposed: pain-related and proprioceptive-related. Pain-related mechanisms predominate in the development of headaches, while proprioceptive mechanisms predominate in cervicogenic dizziness and oculomotor control deficits.

Studies of the primary afferent connections of neurons in the C2 dorsal root ganglion [81] indicate that the following structures receive mono-synaptic inputs from these afferents:

- Lateral cervical nucleus
- Central cervical nucleus
- Caudal projections to C5 level
- Cuneate nucleus, lateral cuneate nucleus
- Nucleus tractus solitarius
- Intercalatus nucleus
- Nucleus X of the vestibular system

‘Upper cervical afferents’ are clearly capable of evoking activity in the vestibular system.

Richmond [81] reported that afferents from deep spinal structures such as those likely to be injured in cervical acceleration injuries terminate in deeper laminae in the dorsal horn than do cutaneous afferents. It is well known that afferents from the C2 and C3 dorsal root ganglia terminate on the same second-order dorsal horn neurons as do many nociceptive afferents arising from the trigeminal sensory nucleus, especially those in the subnucleus caudalis of the descending tract of the trigeminal nerve [82-85]. In fact, Bogduk has termed this continuous column of cells the ‘trigemino-cervical nucleus,’ while Gobel has called it the ‘medullary dorsal horn’ [86]. This critical convergence phenomenon provides a mechanism for referred pain from upper cervical structures (from C0 to at least C3) to the upper cranium and forehead, mimicking headache.

Human studies of pain provocation [87-89] and pain abolition [90,91] have replicated these patterns of cranial pain referral, which can so easily be described by patients as headache. Animal studies of pain provocation in the upper cervical spine [92-95] as well as lower cervical muscles [96,97] report activations of EMG in the cranio-cervical muscles as well as findings indicative of central sensitization, all of which could underlie the development of

headache arising from injury to the deep tissues of the upper cervical spine.

The concept of ‘cervicogenic vertigo’ is less established in the mainstream neurologic literature. Mechanisms underlying this phenomenon rely on both monosynaptic and polysynaptic reflex pathways from the upper cervical spine afferents (associated with a rich innervation from joint and muscle proprioceptors in the cervical spine) to the brainstem structures associated with balance.

Both the cervico-colic and cervico-ocular reflexes work in conjunction with the vestibulo-ocular reflex to stabilize the head and trunk during head/neck motions (CCR) and to stabilize gaze during head rotations (COR). Disturbances in these reflexes can, therefore, initiate balance disturbances and symptoms associated with this problem, particularly those associated with disturbances of eye gaze control [98-100].

Investigating the connection between cervical spine injury and balance disturbances has included studies of increased postural sway and impaired head repositioning capability in whiplash patients [24,99-102] as well as numerous clinical reports of relief of vertigo-like symptoms following treatments to the neck in post-concussion or post-traumatic headache (PCH) patients [103-105]. However, direct evidence of such a link is somewhat scanty. Aside from the work of De Jong et al., mentioned above [106], Vuillerme and Pinsault [107] induced balance disturbances in 16 healthy males after experimental upper cervical pain. Additionally, studies employing vibration of the cervical muscles, presumably to activate muscle spindle output, and, especially in a unilateral fashion, have shown induced postural imbalance and dizziness in normal subjects [108,109].

Remarkably, only two studies have been found that directly examine the presence of cervical dysfunction findings in PCS patients who were involved in relatively low-energy injuries. Treleaven et al. [79] studied 12 post-concussion subjects with PCH and found that the PCH group was distinguished from the normal control group by the presence of painful upper cervical segmental joint dysfunction, less endurance in the neck flexor muscles and a higher incidence of moderately tight neck musculature. They concluded that upper cervical joint dysfunction, which is precisely the disturbance referred to above, should be assessed for in post-concussion headache. Second, a treatment study conducted by Jensen et al. [110], examined 23 patients with persistent PCH an average of 359 days post-concussion (range 302–423 days). The authors found that 18 of the 19 patients available for follow-up had painful upper cervical joint restrictions when compared to an uninjured control group ($n = 19$). The researchers then randomly assigned the PCH group to one of two treatment groups: the manual therapy group, which received mobilizations of the cervical spine as well as a form of assisted muscle stretching, or the cold-pack group, in which subjects were put on an ice pack under their neck and shoulders for 15–20 min. After only two visits, spaced 1 week apart, the manual therapy group had a 57% reduction of their pre-injury pain scores whereas the cold-pack group showed no reduction in headache frequency or intensity. Interestingly, the manual therapy group also had a reduction in analgesic use as well as a 52% reduction in dizziness and visual

disturbance ratings. A more recent randomized controlled trial from the University of Calgary highlighted very similar findings in which weekly treatments focusing on cervical spine and vestibular rehab in subacute and chronic concussion patients resulted in 73% of athletes becoming asymptomatic and cleared to return to sport versus only 7% in a group that did not receive this therapy [111].

Cases

The following is a case-series of five patients who presented to one of our Canadian multidisciplinary concussion clinics with persistent symptoms following a diagnosed concussion sustained anywhere from 5 weeks to 31 months prior to presentation. All subjects underwent concussion evaluation, full neurological examination, including cranial nerve screen, cerebellar testing, as well as upper and lower limb neurological examination. All neurological examinations were unremarkable, aside from one patient (patient 3) who complained of persistent tinnitus and showed conductive hearing loss on the right side. Subsequent referral to an otolaryngologist revealed no abnormalities in this patient. A summary of these patient cases can be found below (Table 2).

Case 1

A 25-year-old male professional mixed martial arts athlete presented 4 months after injury, which was sustained while sparring during a training session. The athlete was thrown to the ground striking the posterior aspect of his head on the mat. Symptoms of headache, dizziness and nausea persisted

for roughly 1 week following injury and he attempted to return to training; however, was unable to do so due to symptom exacerbation and was subsequently referred to a neurologist. The patient saw two separate neurologists and was put on absolute physical and cognitive rest following each of his three follow-up visits spaced 1 month apart. MRI examinations were unremarkable. This patient had a history of four previous concussions; however, all had resolved completely within 1 week. Upon presentation to our clinic the patient complained of numerous post-concussion symptoms the most notable of which were daily headaches, dizziness, noise sensitivity, and an alternating cold and hot sensation in the posterior aspect of the head. The headaches were localized to the frontal area of the forehead as well as bilaterally in the temporal regions.

The patient was put through the Balke physical exertion protocol to assess for blood flow abnormalities according to Leddy et al., 2010 and 2011, and Baker et al., 2012 [112-114]. The patient was able to fully complete the test with no exacerbation of symptoms and was subsequently permitted to return to non-contact exercise and training. Examination of the cervical spine revealed a painful and restricted C2/3 joint on the left side with no referral to the cranium. Palpation of the longus colli, suboccipital triangle, sternocleidomastoid (SCM) and splenius capitis, however, all created referral into the head in the same pattern as the daily headaches experienced by the patient.

A course of treatment was initiated consisting of passive soft tissue therapy using Active Release Therapy (ART[®]) and localized vibration therapy over the affected muscles, as well as active deep-neck flexor endurance training utilizing a

Table 2. Summary chart of patient cases presenting with persistent post-concussion symptoms.

Case	Age, Sex	MOI	Time (weeks)	Symptoms	Balke	Treatment	Outcome
1	25, m	Sparring – contact with posterior head on ground	16	Headache, dizziness, noise sensitivity	Pass	ART [®] of affected muscles, SMT of cervical spine, LV, DNFE	- 3 tx significant reduction in symptoms - 8 tx full resolution of all symptoms
2	59, f	Slip and fall – contact with posterior head on ground	124	Headache, dizziness, anxiety	Pass	ART [®] , Mobilizations of cervical spine, DNFE, Vestibular rehab with head and eye movement included	- 3 months of treatment - 2x/week showed significant subjective improvement - patient still seeking ongoing care on a monthly basis due to fear of aggravation
3	19, m	Hockey – check to head	96	Headache, dizziness, visual problems, fatigue, sensitivity to light, mental foggi-ness, concentration difficulties, irritability, memory difficulties	Pass	ART [®] , SMT of cervical spine, eventual referral to performance optometrist for co-management	- Case ongoing - 80% reduction in symptom severity after 4 tx over a 21-day period
4	19, m	Car accident	14	Headache, irritability, sleep disturbances, visual difficulties, concentration problems, neck pain	Pass	ART [®] , SMT cervical spine, DNFE, Visual tracking exercises, eventual referral to performance optometrist	47% reduction in symptom severity score after 1 tx - 8 tx – full resolution of all symptoms
5	51, f	Hockey – blow to left side of head (temporal region)	5	Daily headache, neck pain	Not done	ART [®] , SMT cervical spine, home-based ROM exercises	- 3 tx over 6 weeks: full resolution of symptoms

Abbreviations: ART[®] = Active release therapy; DNFE = Deep neck flexor endurance exercises; f = Female; LV = Localized vibration therapy; m = Male; MOI = Mechanism of injury; ROM = Range of motion; SMT = Spinal manipulative therapy (High-velocity, low-amplitude); tx = Treatments.

protocol set forth by Jull et al. [115], which was done by the patient at home. Spinal manipulative therapy (SMT) of the restricted joints was also initiated. The patient was seen on a weekly basis for 30-min treatments. After three visits the patient was back to two training sessions per day with heart rates reaching 190 beats per minute with no exacerbation of symptoms during training. Headache frequency dropped significantly from daily headaches to 1–2 brief headaches per week, which were alleviated with self-palpation/massage over the affected muscles. The patient also no longer experienced feelings of dizziness. On the fourth visit the patient underwent an extreme physical exertion testing procedure developed by the Chicago Blackhawks medical staff and utilized to assess readiness to return to contact sport. The protocol consists of intense anaerobic exercise paired with plyometric and vestibular challenges. The patient was completely asymptomatic throughout the duration of the testing procedure and was permitted to return to light contact in the form of grappling but withheld from engagement in full sparring. Treatment of the cervical spine continued on a weekly basis and by the eighth visit the patient was completely asymptomatic between treatments with training and full contact sparring. The patient was subsequently cleared to return to full competition at the professional level.

Case 2

A 59-year-old female university counselor presented with persistent symptoms of 31 months duration following a slip-and-fall injury where she hit the posterior aspect of her head on the frozen ground. Her initial symptoms at the time of injury were being dazed and having a headache. Over the next 3 weeks her symptoms progressed and she was referred to a neurologist as well as a neurosurgeon. CT and MRI evaluations were unremarkable aside from a congenital fusion visualized at the C2 – C3 level of the cervical spine. She was advised by the neurosurgeon to go on complete mental and physical rest. At each monthly follow-up she was given the same recommendations, which amounted to 9 months of lost work with brief periods of failed attempts at gradual workplace re-integration.

When she presented to our clinic she was finally back to work but was still finding it very difficult with her ongoing headaches and dizziness. Her main complaint of headache was described as ‘someone driving a screwdriver right through the top of my head,’ which increased as the day progressed. The patient was also very anxious and concerned for her condition believing that there was no hope for recovery. All neurological examinations were unremarkable and the patient was put through the Balke physical exertion test. Even though the patient had not exercised since her injury on recommendations from her previous physicians, she was able to pass the Balke treadmill reaching a peak heart rate of 180 beats per minute with no exacerbation of her symptoms.

Examination of her cervical spine revealed several painful zygapophyseal joint restrictions from C0/C1 down to the C4 level bilaterally. Palpation of the soft tissues revealed several painful trigger points, which caused referred pain into the head the worst of which was splenius capitis on the left

side. Splenius capitis palpation recreated the screwdriver sensation at the top of her head. Vestibular testing revealed a negative Dix–Hallpike test for benign paroxysmal positional vertigo and a positive rotatory chair test for cervicogenic vertigo. Further vestibular testing revealed balance impairments when eye movements and neck and head rotations were incorporated. Passive and active treatment of the cervical spine were initiated and consisted of a similar treatment methodology and schedule as seen in Case 1 with the exception of high-velocity low-amplitude cervical spine manipulation as the patient did not wish to have this type of treatment. Low-velocity mobilizations were therefore used. The patient reported excellent symptomatic relief for 2–3 days following each treatment. Additional vestibular rehabilitation incorporating visual motion and head and neck movements during various balance progressions was also utilized.

Treatment visits began on a weekly basis, however, the patient elected to increase frequency to twice per week as they were very effective in significantly reducing her symptoms. At 3 months following the initiation from treatment the patient had continued working, was driving with no issue, and exercising with a personal trainer. Although the patient is currently asymptomatic and has returned to all activities of daily living, she elected to continue with therapy once per month due to personal fear of symptomatic return.

Case 3

This 19-year-old male junior hockey player presented to our clinic as a referral from his family physician following 2 years of post-concussion symptoms resulting from a body check to the left side of his head and body. The contact resulted in initial symptoms of dizziness, tinnitus and headache with no resulting loss of consciousness. Upon presentation to our clinic, the patient reported 17 of a possible 22 symptoms on the post-concussion symptom score (PCSS) with a total symptom severity of 40/132. The highest rated symptoms at presentation were mental foginess, headaches, dizziness, irritability, sleep disturbances and tinnitus. Neurological exam revealed an apparent sensorineural hearing loss on the right side, but was otherwise unremarkable. A referral to an otolaryngologist, as well as an MRI, revealed no abnormalities. A Balke stress test was performed and the patient had no exacerbation of symptoms and reached a heart rate of 178 beats per minute. He was therefore permitted to return to non-contact activity. There were painful joint restrictions at the C0/C1 and C2/C3 levels as well as muscle trigger points in the splenius capitis, temporalis and SCM. Palpation of the suboccipital muscles caused a referred pain to the frontal area of the head mimicking the headaches the patient had been experiencing. A rotatory chair test was also performed and was positive for cervicogenic vertigo. Treatment of the cervical spine, consisting of ART[®] and SMT, was initiated at a frequency of one to two 20–30-min treatments per week. After four treatments the patient reported a significant improvement in his symptoms registering a PCSS of 7 of a possible 22 symptoms and a total severity score of 8/132. His headache scores had reduced from 3/6 to 1/6, dizziness scores reduced from 2/6 to a 0/6, mental foginess reduced from

6/6 to 1/6, irritability reduced from 5/6 to a 0/6, and light sensitivity reduced from 3/6 to a 0/6. At this point, he still complained of some mild visual difficulties particularly with reading and watching television. He was subsequently referred to a performance vision optometrist for co-management of his visual symptoms. At the time of the writing of this paper, his care was still ongoing having only had four visits. This case highlights that some patients with persistent symptoms can have significant improvements in their PCS through various active and passive treatments of the cervical spine in a minimal amount of time. This particular patient had been highly symptomatic for a 2-year period and within 21 days after presentation he had an 80% reduction in his post-concussion symptom severity score.

Case 4

This 19-year-old male junior hockey player presented 14 weeks after sustaining a concussion in a car accident in which he rolled a small convertible several times. CT imaging at the hospital following the injury was unremarkable. Main symptom complaints on presentation were frontal headaches, visual problems, concentration difficulties, neck pain, irritability, emotional lability and sleep difficulties including taking up to 4 h to fall asleep at night. His PCSS at presentation demonstrated 9/22 total symptoms with an overall severity score of 36/132. At the time of presentation, the patient was out of school and sports for two full months on the advice of his family physician. Neurological examination was unremarkable; however, he had some difficulties with visual smooth pursuit, demonstrating saccadic eye movement. On treadmill testing, the patient was able to complete the test with a heart rate of 167 beats per minute with no exacerbation of symptoms.

Examination of the cervical spine revealed several trigger points in splenius capitis, longus colli, suboccipital triangle and the SCM all of which created referral into the head particularly the suboccipitals and SCM bilaterally. He also had painful joint restrictions in the C0/C1, C2/3 and C3/4 facet joints bilaterally.

Treatment of the cervical spine was initiated consisting of ART[®], SMT, as well as deep neck flexor endurance and visual tracking exercises done at home. After the first treatment, the patient reported significant relief of his symptoms. At the beginning of the second visit, the patient's headache score had dropped from 3/6 to 1/6. His total PCSS showed a total of 6 out of a possible 22 symptoms with a total severity score of 19, representing a 53% reduction in symptom severity following only one treatment. Two more treatments were provided the following week and on the fourth visit the patient reported a PCSS of 3/22 with a total severity score of 6/132 and a headache score of 0/6. The patient was also participating in non-contact sport-specific activity (skating) 3–4 h per day, had enrolled in an online adult education course, and reported that he was sleeping better at night. On the seventh visit, the patient reported a PCSS of 2 out of 22 with a total symptom severity score of 2, including a neck pain score of 1/6 as well as a 1/6 rating for blurred vision. At

this point, the patient was referred to a performance vision optometrist for co-management. By the eighth visit, the patient reported that he was doing his visual exercises and that he was already feeling much better, citing a full resolution of all symptoms. He was subsequently put through the Chicago Blackhawks physical exertion testing program and passed with no exacerbation of any of his symptoms and thereby permitted to return to contact sport.

Case 5

This 51-year-old female human resources manager presented 5-weeks after sustaining a concussion while playing in a recreational hockey game in which she collided with an opposing player striking the left side of her head. The patient had no previous history of concussion and her ongoing symptoms were constant daily headaches on the left temporal region and left-sided neck pain on left rotation. All neurological testing was unremarkable. Due to the presence of neck pain, this patient underwent cervical spine examination without first undergoing the Balke treadmill test, which revealed a very painful facet joint restriction at C3/4 on the left. Soft tissue palpation revealed several trigger points in the left suboccipital triangle, longus colli and the SCM; all of which, referred pain into the left temporal region, recreating her headache. Treatment of the cervical spine was initiated including ART[®] to the affected soft tissue trigger points, spinal manipulation to the painful and restricted joints, as well as deep neck flexor endurance exercises in the form of seated chin-tucks performed at home. Thirty-minute treatments were initiated on a weekly basis and after the third treatment the patient was no longer experiencing any headaches but still had some mild neck stiffness from time to time. The patient was given further range of motion exercises and was scheduled for a follow-up 3 weeks later at which she reported that her symptoms of both headaches and neck pain had completely resolved. The patient was subsequently discharged and permitted to resume all activity.

Conclusion

The acute symptoms of concussion are widely considered to be the result of functional neuronal disturbance and an altered cerebral environment however; the etiology of chronic post-concussion symptoms remains unclear. The pathophysiological processes involved in the acute neurometabolic cascade of concussion have been shown by the majority of studies to resolve within a 30-day period. As previously discussed, diffusion tensor examinations of PCS patients also provides inconsistent evidence for neuronal dysfunction as a significant underlying cause of chronic symptoms. Studies utilizing SPECT have found hypoperfusion in various brain regions for up to 5 years following concussion, however, these do not seem specific to concussion injuries, as similar findings are present in myriad physical and psychological conditions. The above findings demonstrate that although the underlying pathophysiology of acute concussion is becoming increasingly well understood, the same cannot be said for the symptoms experienced in PCS.

Based on previously established tissue injury thresholds, acceleration/deceleration of the head–neck complex of sufficient magnitude to cause mTBI is also likely to cause concurrent injury to the joints and soft tissues of the cervical spine. It has also been well established that injury and/or dysfunction of the cervical spine can result in numerous signs and symptoms synonymous with concussion, including headaches, dizziness, as well as cognitive and visual dysfunction; making diagnosis difficult. Due the strong personal, social and economic burdens posed by PCS, we strongly suggest that future research be conducted to further examine the relationship of cervical spine injury contributing to symptomatology in these patients. It is important not only to improve diagnostic procedures but also study the outcome of treatment aimed at ameliorating cervical spine dysfunction in a randomized and controlled fashion.

In conclusion, management of persistent PCS symptoms through ongoing brain rest is outdated and demonstrates limited evidence of effectiveness in these patients. Instead, the cases presented above as well as previous literature in this area produce initial evidence that skilled, manual therapy-related assessment and rehabilitation of cervical spine dysfunction should be considered for chronic symptoms following concussion injuries.

Declaration of interest

The authors have no relevant affiliations or financial involvement with any organization or entity with a financial interest in or financial conflict with the subject matter or materials discussed in the manuscript. This includes employment, consultancies, honoraria, stock ownership or options, expert testimony, grants or patents received or pending, or royalties.

References

- [1] Langlois JA, Rutland-Brown W, Wald MM. The epidemiology and impact of traumatic brain injury: a brief overview. *J Head Trauma Rehabil* 2006;21:375–8.
- [2] Thompson J, Sebastianelli W, Slobounov S. EEG and postural correlates of mild traumatic brain injury in athletes. *Neurosci Lett* 2005;377:158–63.
- [3] McCrory P, Meeuwisse WH, Aubry M, Cantu B, Dvorak J, Echemendia RJ, et al. Consensus statement on concussion in sport: the 4th International Conference on Concussion in Sport held in Zurich, November 2012. *Br J Sports Med* 2013;47:250–8.
- [4] Bigler ED. Neuropsychology and clinical neuroscience of persistent post-concussive syndrome. *J Int Neuropsychol Soc* 2007;14:1–22.
- [5] Williams M, Williamson E, Gates S, Lamb S, Cooke M. A systematic literature review of physical prognostic factors for the development of Late Whiplash Syndrome. *Spine* 2007;32:E764–80.
- [6] Leddy JJ, Kozlowski KK, Fung MM, Pendergast DRD, Willer BB. Regulatory and autoregulatory physiological dysfunction as a primary characteristic of post concussion syndrome: implications for treatment. *NeuroRehabilitation* 2007;22:199–205.
- [7] Leddy JJ, Sandhu H, Sodhi V, Baker JG, Willer B. Rehabilitation of concussion and post-concussion syndrome. *Sports Health* 2012;4:147–54.
- [8] Boake C, McCauley SR, Levin HS, Pedroza C, Contant CF, Song JX, et al. Diagnostic criteria for postconcussional

- syndrome after mild to moderate traumatic brain injury. *J Neuropsychiatry Clin Neurosci* 2005;17:350–6.
- [9] Jotwani V, Harmon KG. Postconcussion syndrome in athletes. *Curr Sports Med Rep* 2010;9:21–6.
- [10] Giza CC, Hovda DA. The neurometabolic cascade of concussion. *J Athl Train* 2001;36:228–35.
- [11] Len TK, Neary JP, Asmundson GJG, Goodman DG, Bjornson B, Bhambhani YN. Cerebrovascular reactivity impairment after sport-induced concussion. *Med Sci Sports Exerc* 2011;43:2241–8.
- [12] Len TK, Neary JP. Cerebrovascular pathophysiology following mild traumatic brain injury. *Clin Physiol Funct Imaging* 2010;31:85–93.
- [13] Vagnozzi R, Signoretti S, Cristofori L, Alessandrini F, Floris R, Isgro E, et al. Assessment of metabolic brain damage and recovery following mild traumatic brain injury: a multicentre, proton magnetic resonance spectroscopic study in concussed patients. *Brain* 2010;133:3232–42.
- [14] Signoretti S, Lazzarino G, Tavazzi B, Vagnozzi R. The pathophysiology of concussion. *PM R* 2011;3:S359–68.
- [15] Prigatano GP, Gale SD. The current status of postconcussion syndrome. *Curr Opin Psychiatry* 2011;24:243–50.
- [16] Vagnozzi R, Tavazzi B, Signoretti S, Amorini AM, Belli A, Cimatti M, et al. Temporal window of metabolic brain vulnerability to concussions. *Neurosurgery* 2007;61:379–89.
- [17] Signoretti S, Vagnozzi R, Tavazzi B, Lazzarino G. Biochemical and neurochemical sequelae following mild traumatic brain injury- summary of experimental data and clinical implications - 2010. *Neurosurg Focus* 2010;29:1–12.
- [18] Broglio SP, Surma T, Ashton-Miller JA. High school and collegiate football athlete concussions: A biomechanical review. *Ann Biomed Eng* 2011;40:37–46.
- [19] Spitzer WO, Skovron ML, Salmi LR, Cassidey JD, Duranceau J, Suissa S, et al. Scientific monograph of the Quebec Task Force on Whiplash-Associated Disorders: redefining whiplash and its management. *Spine* 1995;20:1S–73S.
- [20] Evans RW. Persistent post-traumatic headache, postconcussion syndrome, and whiplash injuries: the evidence for a non-traumatic basis with an historical review. *Headache* 2010;50:716–24.
- [21] Evans RW. Chronic whiplash syndrome. *Neurology* 1995;45:2117–18.
- [22] Haldorsen T, Waterloo K, Dahl A, Mellgren SI, Davidsen PE, Molin PK. Symptoms and cognitive dysfunction in patients with the late whiplash syndrome. *Appl Neuropsychol* 2003;10:170–5.
- [23] Freitag P, Greenlee MW, Wachter K, Ettl TM, Radue EW. fMRI Response during visual motion stimulation in patients with late whiplash syndrome. *Neurorehabil Neural Repair* 2001;15:31–7.
- [24] Findling O, Schuster C, Sellner J, Ettl T, Allum JHJ. Trunk sway in patients with and without, mild traumatic brain injury after whiplash injury. *Gait Posture* 2011;34:473–8.
- [25] Radanov BP, Dvorak J, Valach L. Cognitive deficits in patients after soft tissue injury of the cervical spine. *Spine* 1992;17:127–31.
- [26] Gimse R, Björger IA, Tjell C, Tyssedal JSL, Bø K. Reduced cognitive functions in a group of whiplash patients with demonstrated disturbances in the posture control system. *J Clin Exp Neuropsychol* 1997;19:838–49.
- [27] Yadla S, Ratliff JK, Harrop JS. Whiplash: diagnosis, treatment, and associated injuries. *Curr Rev Musculoskelet Med* 2007;1:65–8.
- [28] Rubin AMA, Woolley SMS, Dailey VMV, Goebel JAJ. Postural stability following mild head or whiplash injuries. *Am J Otol* 1995;16:216–21.
- [29] Hynes LM, Dickey JP. Is there a relationship between whiplash-associated disorders and concussion in hockey? A preliminary study. *Brain Inj* 2006;20:179–88.
- [30] Sizer J, Phelps V, Brismee JM. Diagnosis and management of cervicogenic headache and local cervical syndrome with multiple pain generators. *J Man Manip Ther* 2002;10:136–52.
- [31] Vincent MB. Headache and neck. *Curr Pain Headache Rep* 2011;15:324–31.

- [32] Ruhe A, Fejer R, Walker B. Altered postural sway in patients suffering from non-specific neck pain and whiplash associated disorder - A systematic review of the literature. *Chiropr Man Therap* 2011;19:13.
- [33] Silva AG, Cruz AL. Standing balance in patients with whiplash-associated neck pain and idiopathic neck pain when compared with asymptomatic participants: A systematic review. *Physiother Theory Pract* 2012;29:1–18.
- [34] Kristjansson E, Treleaven J. Sensorimotor function and dizziness in neck pain: implications for assessment and management. *J Orthop Sports Phys Ther* 2009;39:364–77.
- [35] Treleaven J. Sensorimotor disturbances in neck disorders affecting postural stability, head and eye movement control. *Man Ther* 2008;13:2–11.
- [36] Lord SM, Barnsley L, Wallis BJ, McDonald GJ, Bogduk N. Percutaneous radio-frequency neurotomy for chronic cervical zygapophyseal-joint pain. *N Engl J Med* 1996;335:1721–6.
- [37] Radanov BP, Bicik I, Dvorak J, Antinnes J, Schulthess von GK, Buck A. Relation between neuropsychological and neuroimaging findings in patients with late whiplash syndrome. *J Neurol Neurosurg Psychiatry* 1999;66:485–9.
- [38] Vagnozzi R, Marmarou A, Tavazzi B, Signoretti S, Di Pierro D, Del Bolgia F, et al. Changes of cerebral energy metabolism and lipid peroxidation in rats leading to mitochondrial dysfunction after diffuse brain injury. *J Neurotrauma* 1999;16:903–13.
- [39] Signoretti S, Marmarou A, Tavazzi B, Lazzarino G, Beaumont A, Vagnozzi R. N-Acetylaspartate reduction as a measure of injury severity and mitochondrial dysfunction following diffuse traumatic brain injury. *J Neurotrauma* 2001;18:977–91.
- [40] Signoretti S, Vagnozzi R, Tavazzi B, Lazzarino G. Biochemical and neurochemical sequelae following mild traumatic brain injury: summary of experimental data and clinical implications. *Neurosurg Focus* 2010;29:E1.
- [41] Vagnozzi RR, Signoretti SS, Tavazzi BB, Floris RR, Ludovici AA, Marziali SS, et al. Temporal window of metabolic brain vulnerability to concussion: a pilot 1H-magnetic resonance spectroscopic study in concussed athletes—part III. *Neurosurgery* 2008;62:1286–95.
- [42] Nakabayashi M, Suzaki S, Tomita H. Neural injury and recovery near cortical contusions: a clinical magnetic resonance spectroscopy study. *J Neurosurg* 2007;106:370–7.
- [43] Chen J, Jin H, Zhang Y, Liang Q, Liao H, Guo Z, et al. MRS and diffusion tensor image in mild traumatic brain injuries. *Asian Pac J Trop Med* 2011;5:67–70.
- [44] Henry LC, Tremblay S, Leclerc S, Khiat A, Boulanger Y, Ellemberg D, et al. Metabolic changes in concussed American football players during the acute and chronic post-injury phases. *BMC Neurol* 2011;11:1–10.
- [45] Lin AP, Liao HJ, Merugumala SK, Prabhu SP, Meehan WP, Ross BD. Metabolic imaging of mild traumatic brain injury. *Brain Imaging Behav* 2012;6:208–23.
- [46] Sarmiento E, Moreira P, Brito C, Souza J, Jevoux C, Bigal M. Proton spectroscopy in patients with post-traumatic headache attributed to mild head injury. *Headache* 2009;49:1345–52.
- [47] Bartnik-Olson BL, Holshouser B, Wang H, Grube M, Tong K, Wong V, et al. Impaired neurovascular unit function contributes to persistent symptoms after concussion: a pilot study. *J Neurotrauma* 2014;31:1497–506.
- [48] Lazzarino G, Vagnozzi R, Signoretti S, Manara M, Floris R, Amorini AM, et al. The importance of restriction from physical activity in the metabolic recovery of concussed brain. In Agrawal A, Editor *Brain injury: pathogenesis, monitoring, recovery and management*. Rijeka, Croatia: InTech; 2012. p 501–22.
- [49] Aoki Y, Inokuchi R, Gunshin M, Yahagi N, Suwa H. Diffusion tensor imaging studies of mild traumatic brain injury: a meta-analysis. *J Neurol Neurosurg Psychiatry* 2012;83:870–6.
- [50] Cubon VA, Putukian M, Boyer C, Dettwiler A. A diffusion tensor imaging study on the white matter skeleton in individuals with sports-related concussion. *J Neurotrauma* 2011;28:189–201.
- [51] Farhadi HF, Lonser RR. Diffusion tensor imaging in the spotlight on concussion. *World Neurosurg* 2013;80:794–5.
- [52] Messé A, Caplain S, Parodat G, Garrigue D, Mineo J-F, Soto Ares G, et al. Diffusion tensor imaging and white matter lesions at the subacute stage in mild traumatic brain injury with persistent neurobehavioral impairment. *Hum Brain Mapp* 2010;32:999–1011.
- [53] Slobounov S, Gay M, Johnson B, Zhang K. Concussion in athletics: ongoing clinical and brain imaging research controversies. *Brain Imaging Behav* 2012;6:224–43.
- [54] Gajawelli N, Lao Y, Apuzzo MLJ, Romano R, Liu C, Tsao S, et al. Neuroimaging changes in the brain in contact versus non-contact sport athletes using diffusion tensor imaging. *World Neurosurg* 2013;80:824–8.
- [55] Dodd AB, Epstein K, Ling J, Mayer A. Diffusion tensor imaging findings in semi-acute mild traumatic brain injury. *J Neurotrauma* 2014;31:1235–48.
- [56] Henry LC, Tremblay J, Tremblay S, Lee A, Brun C, Lepore N, et al. Acute and chronic changes in diffusivity measures after sports concussion. *J Neurotrauma* 2011;28:2049–59.
- [57] Kasahara K, Hashimoto K, Abo M, Senoo A. Voxel- and atlas-based analysis of diffusion tensor imaging may reveal focal axonal injuries in mild traumatic brain injury — comparison with diffuse axonal injury. *Mag Reson Imaging* 2012;30:496–505.
- [58] Smits M, Houston GC, Dippel DWJ, Wielopolski PA, Vernooij MW, Koudstaal PJ, et al. Microstructural brain injury in post-concussion syndrome after minor head injury. *Neuroradiology* 2010;53:553–63.
- [59] Zhang K, Johnson B, Pennell D, Ray W, Sebastianelli W, Slobounov S. Are functional deficits in concussed individuals consistent with white matter structural alterations: combined FMRI & DTI study. *Exp Brain Res* 2010;204:57–70.
- [60] Lange RT, Iverson GL, Brubacher JR, Mädlar B, Heran MK. Diffusion tensor imaging findings are not strongly associated with postconcussional disorder 2 months following mild traumatic brain injury. *J Head Trauma Rehabil* 2012;27:188–98.
- [61] Koerte IK, Kaufmann D, Hartl E, Bouix S, Pasternak O, Kubicki M, et al. A prospective study of physician-observed concussion during a varsity university hockey season: white matter integrity in ice hockey players. Part 3 of 4. *Neurosurg Focus* 2012;33:E3.
- [62] Bazarian JJ, Zhu T, Blyth B, Borrino A, Zhong J. Subject-specific changes in brain white matter on diffusion tensor imaging after sports-related concussion. *Mag Reson Imaging* 2012;30:171–80.
- [63] Hutchinson M, Comper P, Csenge B, Richards D. Psychosocial and psychological factors related to delayed recovery from concussion in high school students. *Br J Sports Med* 2014;48:610.
- [64] Mander M, Larysz D, Wojtacha M. Changes in cerebral hemodynamics assessed by transcranial Doppler ultrasonography in children after head injury. *Childs Nerv Syst* 2002;18:124–8.
- [65] Chan KH, Dearden NM, Miller JD. The significance of posttraumatic increase in cerebral blood flow velocity: a transcranial Doppler ultrasound study. *Neurosurgery* 1992;30:697–700.
- [66] Jünger EC, Newell DW, Grant GA, Avellino AM, Ghatan S, Douville CM, et al. Cerebral autoregulation following minor head injury. *J Neurosurg* 1997;86:425–32.
- [67] Len TK, Neary JP, Amundson GJG, Candow DG, Goodman DG, Bjornson B, et al. Serial monitoring of CO₂ reactivity following sport concussion using hypocapnia and hypercapnia. *Brain Inj* 2013;27:346–53.
- [68] Gall B, Parkhouse W, Goodman D. Heart rate variability of recently concussed athletes at rest and exercise. *Med Sci Sports Exerc* 2004;36:1269–74.
- [69] Gray BG, Ichise M, Chung DG, Kirsh JC, Franks W. Technetium-99m-HMPAO SPECT in the evaluation of patients with a remote history of traumatic brain injury: a comparison with x-ray computed tomography. *J Nucl Med* 1992;33:52–8.
- [70] Ichise M, Chung DG, Wang P, Wortzman G, Gray BG, Franks W. Technetium-99m-HMPAO SPECT, CT and MRI in the evaluation of patients with chronic traumatic brain injury: a correlation with neuropsychological performance. *J Nucl Med* 1994;35:217–26.
- [71] Bonne O. Cerebral blood flow in chronic symptomatic mild traumatic brain injury. *Psychiatry Res* 2003;124:141–52.
- [72] Lewine JD, Davis JT, Bigler ED, Thoma R, Hill D, Funke M, et al. Objective documentation of traumatic brain injury subsequent to mild head trauma: multimodal brain imaging with MEG, SPECT, and MRI. *J Head Trauma Rehabil* 2007;22:141–55.

- [73] Bakhtadze MA, Vernon H, Karalkin AV, Pasha SP, Tomashevskiy IO, Soave D. Cerebral perfusion in patients with chronic neck and upper back pain: preliminary observations. *J Manip Physiol Ther* 2012;35:76–85.
- [74] Otte A, Mueller-Brand J, Fierz L. Brain SPECT findings in late whiplash syndrome. *Lancet* 1995;345:1513–14.
- [75] Nakamura Y, Nojiri K, Yoshihara H, Takahata T, Honda-Takahashi K, Kubo S, et al. Significant differences of brain blood flow in patients with chronic low back pain and acute low back pain detected by brain SPECT. *J Orthop Sci* 2014;19:384–9.
- [76] Alptekin K, Degirmenci B, Kivircik B, Durak H, Yemez B, Derebek E, et al. Tc-99m HMPAO brain perfusion SPECT in drug-free obsessive-compulsive patients without depression. *Psychiatry Res* 2001;107:51–6.
- [77] Ito HH, Kawashima RR, Awata SS, Ono SS, Sato KK, Goto RR, et al. Hypoperfusion in the limbic system and prefrontal cortex in depression: SPECT with anatomic standardization technique. *J Nucl Med* 1996;37:410–14.
- [78] Schwartz RB, Komaroff AL, Garada BM, Gleit M, Doolittle TH, Bates DW, et al. SPECT imaging of the brain: comparison of findings in patients with chronic fatigue syndrome, AIDS dementia complex, and major unipolar depression. *Am J Roentgenol* 1994;162:943–51.
- [79] Treleaven J, Jull G, Atkinson L. Cervical musculoskeletal dysfunction in post-concussional headache. *Cephalalgia* 1994;14:273–57.
- [80] Schneider KJ, Meeuwisse WH, Kang J, Schneider GM, Emery CA. Preseason reports of neck pain, dizziness, and headache as risk factors for concussion in male youth ice hockey players. *Clin J Sport Med* 2013;23:267–72.
- [81] Richmond FJR, Corneil BD. Afferent mechanisms in the upper cervical spine. In Vernon H, Editor *The cranio-cervical syndrome: mechanisms, assessment, and treatment*. Oxford, UK: Butterworth Heinemann; 2003. p 14–30.
- [82] Bogduk N. Mechanisms and pain patterns of the upper cervical spine. In Vernon H, Editor *The cranio-cervical syndrome: mechanisms, assessment and treatment*. Oxford, UK: Butterworth Heinemann; 2003. p 110–16.
- [83] Hu J, Tsai CM, Bakke M, Seo K, Tambeli CH, Vernon H. Deep craniofacial pain: involvement of trigeminal subnucleus caudalis and its modulation. *Prog Pain Res Manag* 1997;8:497–506.
- [84] Sessle BJ. Recent insights into brainstem mechanisms underlying craniofacial pain. *J Dent Educ* 2002;66:108–12.
- [85] Mørch CD, Hu JW, Arendt-Nielsen L, Sessle BJ. Convergence of cutaneous, musculoskeletal, dural and visceral afferents onto nociceptive neurons in the first cervical dorsal horn. *Eur J Neurosci* 2007;26:142–54.
- [86] Gobel S, Hockfield S, Ruda MA. Anatomical similarities between medullary and spinal dorsal horns. In Kawamura Y, Dubner R, Editors *Orofacial sensory and motor functions*. Tokyo: Quintessence; 1981. p 211–23.
- [87] Roth JK, Roth RS, Weintraub JR, Simons DG. Cervicogenic headache caused by myofascial trigger points in the sternocleidomastoid: a case report. *Cephalalgia* 2007;27:375–80.
- [88] Fernández-de-las-Peñas C, Cuadrado ML, Arendt-Nielsen L, Simons DG, Pareja JA. Myofascial trigger points and sensitization: an updated pain model for tension-type headache. *Cephalalgia* 2007;27:383–93.
- [89] Lord SM. The cervical synovial joints as sources of post-traumatic headache. *J Musculoskel Pain* 1996;4:81–94.
- [90] Aprill C, Dwyer A, Bogduk N. Cervical zygapophyseal joint pain patterns. II: A clinical evaluation. *Spine* 1990;15:458–61.
- [91] Cooper G, Bailey B, Bogduk N. Cervical zygapophysial joint pain maps. *Pain Med* 2007;8:344–53.
- [92] Hu JW, Yu XM, Vernon H, Sessle BJ. Excitatory effects on neck and jaw muscle activity of inflammatory irritant applied to cervical paraspinal tissues. *Pain* 1993;55:243–50.
- [93] Hu JW, Sun KQ, Vernon H, Sessle BJ. Craniofacial inputs to upper cervical dorsal horn: Implications for somatosensory information processing. *Brain Res* 2005;1044:93–106.
- [94] Shin P, Vernon H, Sessle BJ, Hu JW. Neck muscle length modulates nociceptive reflex evoked by noxious irritant application to rat neck tissues. *Exp Brain Res* 2005;163:314–23.
- [95] Vernon H, Sun K, Zhang Y, Yu XM, Sessle BJ. Central sensitization induced in trigeminal and upper cervical dorsal horn neurons by noxious stimulation of deep cervical paraspinal tissues in rats with minimal surgical trauma. *J Manip Physiol Ther* 2009;32:506–14.
- [96] Panfil C, Makowska A, Ellrich J. Brainstem and cervical spinal cord Fos immunoreactivity evoked by nerve growth factor injection into neck muscles in mice. *Cephalalgia* 2006;26:128–35.
- [97] Makowska A, Panfil C, Ellrich J. Nerve growth factor injection into semispinal neck muscle evokes sustained facilitation of the jaw-opening reflex in anesthetized mice? possible implications for tension-type headache. *Exp Neurol* 2005;191:301–9.
- [98] Gimse R, Tjell C, Bjorgen IA, Saunte C. Disturbed eye movements after whiplash due to injuries to the posture control system. *J Clin Exp Neuropsychol* 1996;18:178–86.
- [99] Heikkilä HV, Wenngren B-I. Cervicocephalic kinesthetic sensibility, active range of cervical motion, and oculomotor function in patients with whiplash injury. *Arch Phys Med Rehabil* 1998;79:1089–94.
- [100] Treleaven J, Jull G, LowChoy N. The relationship of cervical joint position error to balance and eye movement disturbances in persistent whiplash. *Man Ther* 2006;11:99–106.
- [101] Treleaven J. Sensorimotor disturbances in neck disorders affecting postural stability, head and eye movement control—Part 2: Case studies. *Man Ther* 2008;13:266–75.
- [102] Treleaven J, Jull G, Sterling M. Dizziness and unsteadiness following whiplash injury: characteristic features and relationship with cervical joint position error. *J Rehabil Med* 2003;35:36–43.
- [103] Palmgren PJ, Sandström PJ, Lundqvist FJ, Heikkilä H. Improvement after chiropractic care in cervicocephalic kinesthetic sensibility and subjective pain intensity in patients with nontraumatic chronic neck pain. *J Manip Physiol Ther* 2006;29:100–6.
- [104] Bracher ES, Almeida CI, Almeida RR, Duprat AC, Bracher CB. A combined approach for the treatment of cervical vertigo. *J Manip Physiol Ther* 2000;23:96–100.
- [105] Mahlstedt K, Westhofen M, König K. Therapy of functional disorders of the craniovertebral joints in vestibular disease. *Laryngorhinologie* 1992;71:246–50.
- [106] de Jong PT, de Jong JM, Cohen B, Jongkees LB. Ataxia and nystagmus induced by injection of local anesthetics in the neck. *Ann Neurol* 1977;1:240–6.
- [107] Vuillerme N, Pinsault N. Experimental neck muscle pain impairs standing balance in humans. *Exp Brain Res* 2008;192:723–9.
- [108] Yacovino DA. Neck vibration: usefulness in neurotology. *Rev Neurol* 2004;38:1061–6.
- [109] Holmberg J, Karlberg M, Fransson PA, Magnusson M. Phobic postural vertigo: body sway during vibratory proprioceptive stimulation. *Neuroreport* 2003;14:1007–11.
- [110] Jensen OK, Nielsen FF, Vosmar L. An open study comparing manual therapy with the use of cold packs in the treatment of post-traumatic headache. *Cephalalgia* 1990;10:241–50.
- [111] Schneider KJ, Meeuwisse WH, Nettel-Aguirre A, Barlow K, Boyd L, Kang J, et al. Cervicovestibular rehabilitation in sport-related concussion: a randomised controlled trial. *Br J Sports Med* 2014;48:1294–8.
- [112] Leddy JJ, Baker JG, Kozlowski K, Bisson L, Willer B. Reliability of a graded exercise test for assessing recovery from concussion. *Clin J Sport Med* 2011;21:89–94.
- [113] Leddy JJ, Kozlowski K, Donnelly JP, Pendergast DR, Epstein LH, Willer B. A preliminary study of subsymptom threshold exercise training for refractory post-concussion syndrome. *Clin J Sport Med* 2010;20:21–7.
- [114] Baker JG, Freitas MS, Leddy JJ, Kozlowski KF, Willer BS. Return to full functioning after graded exercise assessment and progressive exercise treatment of postconcussion syndrome. *Rehabil Res Pract* 2012;2012:1–7.
- [115] Jull G, Kristjansson E, Dall'Alba P. Impairment in the cervical flexors: a comparison of whiplash and insidious onset neck pain patients. *Man Ther* 2004;9:89–94.
- [116] Marshall CM. Sports-related concussion: A narrative review of the literature. *J Can Chiropr Assoc* 2012;56:299–310.